

MAM14 Immunotherapy Protocol: The Dream of Ophthalmologist, Became at Your Door.

This Protocol Can Treat Autoimmune Uveitis.

Saleh A. Alharbi^{a*}, Ali S. Alharbi^b, Sami Alrabea^c

^aMOH, Kuwait, affiliated to Kuwait University, Faculty of Medicine, Jabrya, Kuwait, 13060 . (Kuwait University Grant # MI067; MI068.)

^bMOH, Kuwait, affiliated to Kuwait University, Faculty of Pharmacy, Jabrya , Kuwait, 13060.

^cMOH, Kuwait. 13001

^aEmail: saleh129@gmail.com

^bEmail: imunodoc@gmail.com

Abstract

Uveitis doesn't have to involve a lifelong treatment course (C Stephen Foster). In this article we replaced conventional steroid and other immunosuppressant treatment by safe and new immunomodulation called MAM14 immunotherapy protocol, designed to treat uveitis. Our objective is to replace steroid and other immunosuppressant with safe effective immunomodulation method. As a first trial to study this protocol, we choose one hundred twelve female uveitis patients called: experimental group; their age range between 13-15 years old, treated by MAM14 immunotherapy, which is briefly, paternal stressed allogeneic lymphocyte vaccination given subcutaneously to their daughters. Compared to 120 female control group uveitis patients age range between 12-16 years old received routine prednisone eye drops (Pred Forte). Results for the Slit lamp microscope showed that the experimental group demonstrates remarkable improvement duration of treatment four to nine months. Improvement lasted for ten years. No side effect noted during experiment and until this writing compared to control. Pachymeter showed no degradation of cornea and slit lamp showed no lymphocyte infiltration.

* Corresponding author.

E-mail address: saleh129@gmail.com.

On the other hand, symptoms and signs of control group patients is up and down. Lymphocyte infiltration is variable and degradation of cornea is prominent. As a conclusion we can say that it is time for autoimmune uveitis attack to be controlled immunologically.

Keywords: MAM14 immunotherapy; uveitis; steroid; lymphocyte infiltration; cornea degradation.

1. Introduction

Uveitis, or intraocular inflammation, is an important cause of visual loss in the developed world, references [1-3] reported as causing 10% of cases of blindness in the United States, and as being the fifth, sixth, or seventh leading cause of blindness in various studies [2]. Uveitis has a disproportionately high impact in terms of years of potential vision lost and economic effects because it often strikes at a younger age than common age-related eye disorders such as cataract, age-related macular degeneration, and glaucoma[3,4]. The proportion of blindness caused by uveitis may be declining [1], reference [3] presumably because of improving treatment. However, most patients managed in tertiary clinics experience visual loss at some point during their clinical course [5].

On the basis of clinical examination, uveitis can be classified into anterior, intermediate, posterior, or panuveitis – based on which portion of the eye is inflamed. The risk of vision loss is progressively higher along this spectrum [6,7]. In developed countries [5,8], such as the United States, the majority of intermediate uveitis and panuveitis cases, and about one-half the posterior uveitis cases presenting for care to uveitis practices, are presumed to be “autoimmune,” with no evidence of infection, and a limited salutary response to corticosteroid and other anti-inflammatory therapy [9-20]. For non-infectious cases, corticosteroids are the mainstay of treatment in most instances, regardless of the specific syndrome diagnosed [21-23]. Use of systemic corticosteroids – with immunosuppressive drugs when indicated – historically has been the primary method advocated for control of severe cases of uveitis [22].

In order to provide evidence on the relative effectiveness and safety of MAM14 immunotherapy with respect to prednisone therapy, we have undertaken a randomized, controlled clinical trial directly comparing these alternatives for the management of non-infectious uveitis. This report describes the design of the trial, and the baseline characteristics of the patients enrolled into the trial, providing new information about the demographic and clinical characteristics uveitis patients managed in tertiary uveitis practices.

2. Method

Statistic: we used Pearson correlation.

2.1 Uveitis control group treated with Prednisone eye drops (Pred Forte) alone

Prednisolone acetate ophthalmic suspension is a steroid medicine used to treat eye swelling caused by allergy, infection, injury, surgery, or other conditions. The dose is to instill two drops into the conjunctival sac two times daily as long as it takes interrupted for maximum six months period. The uveitis control group used Pred Forte

eye drops plus or minus systemic immunosuppression.

2.2 MAM14 Immunotherapy Protocol

112 Uveitis experiment group treated with MAM14 immunotherapy which is paternal stressed PBL vaccination given subcutaneously (SC).

Peripheral Blood Lymphocytes (PBL) isolated from venous blood by density gradient centrifugation method (28), for the sake of preparing MAM14 immunotherapy .

PBL prepared by Ficoll hypaque technique (28). Cells cultured over night in physiological media , washed , diluted and it will be ready for SC inoculation for the experiment group.

2.3 Slit lamp for measuring lymphocyte infiltration in both experiment and control groups. Cornea degradation measured by pachymeter

Normal corneal thickness is about 540 microns (about half of a millimeter). Thickness is checked with a handheld ultrasound device called a pachymeter. Cornea thickness 520 um and less considered degradation of cornea tissue [29].

3. Results

Between 2005- 2015, 112 female uveitis patients (experimental) and 120 female uveitis control group were enrolled in the present study.

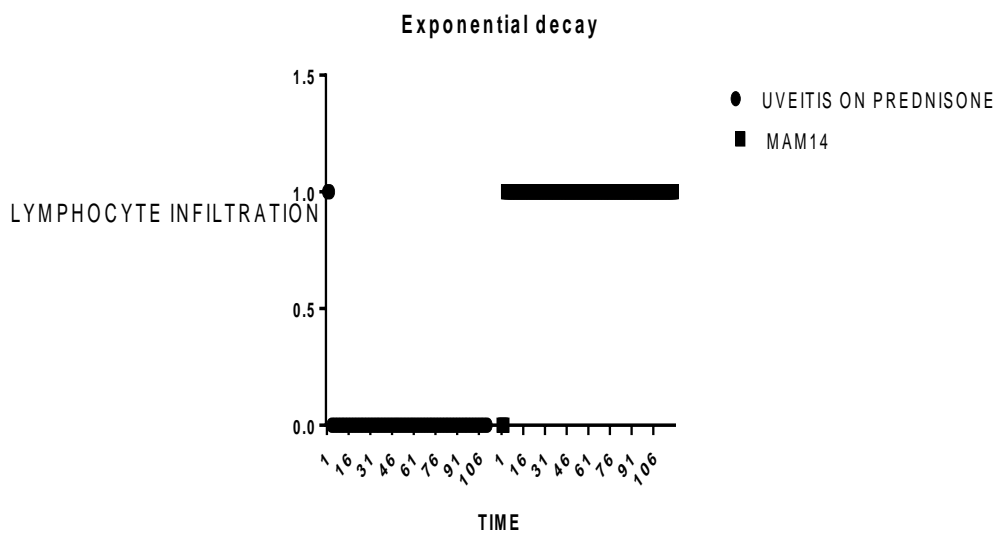


Figure 1: Lymphocyte infiltration

Table 1: statistical results

	INFILTRATION vs. PREDNISON	INFILTRATION vs. MAM14
Pearson r		
r	0.01105	-0.2245
95% confidence interval	-0.1217 to 0.1434	-0.3452 to -0.09658
R squared	0.0001221	0.05042
P value		
P (two-tailed)	0.8708	0.0007
P value summary	ns	***
Significant? (alpha = 0.05)	No	Yes
Number of XY Pairs	219	225

Lymphocyte infiltration improved dramatically in the experiment group who received MAM14 immunotherapy compared to control group.

Figure 1 and Table 1 show dramatic response of the experimental patient group of uveitis compared to control who received eye drops only, Pred forte. ($P < 0.0007$). Lymphocytes infiltration appears in prednisone treated patients in slit lamp exam. No lymphocyte can be seen in slit lamp exam in MAM14 treated patients.

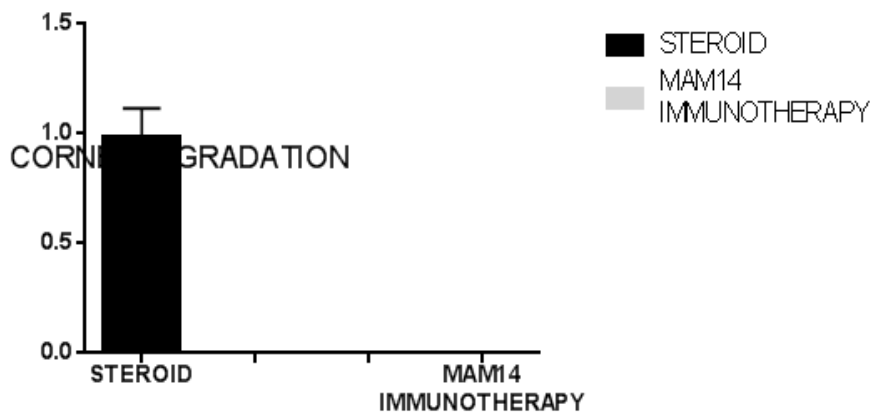


Figure 2: corneal thickness (degradation correlation results)

In this Figure 2, corneal thickness is checked with a handheld ultrasound device called a pachymeter. Showed degradation is prominent (520-500 micron) with steroid eye drops. On the other hand, no degradation (540 micron) seen in patients treated with MAM14 immunotherapy compared to control ($P < 0.05$).

4. Discussion

Steroid reliance too common in treating uveitis. Steroids are valuable, but ...Since the first steroid was administered in a human eye in 1949 by Dan Gordon, M.D., professor at Cornell Medical Center, New York, nothing has come close to its effectiveness for snuffing out inflammation quickly. However, Dr. Gordon, and doctors at the Mayo Clinic who were the first to use systemic steroids to treat patients, soon realized the disturbing side effects of the drug. Within a year, they realized that the chronic use of steroids comes at a fairly high price in terms of side effects that are not desirable, Dr. Foster said. "Most drugs have potential side effects. With corticosteroids, they are 100% guaranteed." When steroids are used locally in the eye long enough, cataracts would be 100% guaranteed. "Thirty percent of the patients who have chronic steroid use end up with elevated IOP and some damage. Despite major inroads in the treatment of many ocular diseases, uveitis rates have remained nearly the same for the past 35 years.

The disease has an estimated prevalence of 38 in 100,000. Of that, 10% of patients will become blind. "The reason that there has been no significant progress in driving down the prevalence in developed countries around the world is because of the exclusive reliance on steroid therapy by the bulk of ophthalmologists who care for patients with uveitis," said C. Stephen Foster, M.D., clinical professor of ophthalmology, Harvard Medical School, Boston. "They do so because that's all they've ever been taught." Dr. Foster is founder and president of the Ocular Immunology and Uveitis Foundation, Massachusetts Eye Research and Surgery Institution, Cambridge. He offered some valuable advice to general ophthalmologists. Look for the pathoimmunogenesis of the disease and think how to manipulate.

In the present study we measured the difference between conventional steroid therapy and MAM 14 immunotherapy. The difference between the two groups of patients is that the long lasting cure showed by the none presence of infiltration of lymphocytes and no degradation in the cornea tissue for the experiment group. Also, no side effect noted during treatment and post treatment period from the immunotherapy protocol. On the other hand, the control group recurrence of signs and symptoms is the rule. Slit lamp microscope exam showed lymphocyte infiltration in the pupil. Also, pachymeter exam showed cornea degradation is remarkable.

The importance of this study Dr. Stephen Foster uncovers, is that the ophthalmologist were a long time ago awaiting for a replacement of steroid to prevent degradation of cornea tissue [26]. This new modality of treatment called MAM14 immunotherapy can fulfill this requirement which is replacement of corticosteroid and other immunosuppressant in managing uveitis. That is why supporting this study will be beneficial for the sake of autoimmune uveitis and other autoimmune disorders [24,25].

5. Conclusion

In summary, MAM14 immunotherapy trial is a phase one effectiveness trial which aims to evaluate whether MAM14 therapy or topical corticosteroid therapy is superior for the management of non-infectious uveitis. We concluded that MAM14 is superior to conventional uveitis therapy.

References

- [1] O. M. Durrani, C. A. Meads, P. I. Murray. (2004). "Uveitis: a potentially blinding disease." *Ophthalmologica*. 218, pp. 223–236.
- [2] R. B. Nussenblatt. (1990). "The natural history of uveitis." *International Ophthalmology*. 14, pp. 303–308.
- [3] J. ten Doesschate. (1982). "Causes of blindness in The Netherlands." *Doc. Ophthalmology*. 52, pp. 279–285.
- [4] National Advisory Eye Council. (1983). "Vision Research. A National Plan 1983-1987." National Institutes of Health, Public Health Service, U.S. Department of Health and Human Services. p. 13.
- [5] O. M. Durrani, N. N. Tehrani, J. E. Marr, P. Moradi, P. Stavrou, P. I. Murray. (2004). "Degree, duration, and causes of visual loss in uveitis." *British Journal of Ophthalmology*. 88, pp. 1159–1162.
- [6] E. Bloch-Michel, R. B. Nussenblatt. (1987). "International Uveitis Study Group recommendations for the evaluation of intraocular inflammatory disease." *American Journal of Ophthalmology*. 103, pp. 234–235.
- [7] D. A. Jabs, R. B. Nussenblatt, J. T. Rosenbaum. (2005). "Standardization of uveitis nomenclature for reporting clinical data. Results of the First International Workshop." *American Journal of Ophthalmology*. 140, pp. 509–516
- [8] A. Rothova, M. S. Suttrop-van Schulten, W. Frits Treffers, A. Kijlstra. (1996) "Causes and frequency of blindness in patients with intraocular inflammatory disease." *British Journal of Ophthalmology*. 80, pp. 332–336.
- [9] D. E. Henderly, A. J. Genstler, R. E. Smith, N. A. Rao. (1987) "Changing patterns of uveitis." *American Journal of Ophthalmology*. 103, pp. 131–136.
- [10] C. A. McCannel, G. N. Holland, C. J. Helm, P. J. Cornell, J. V. Winston, T. G. Rimmer. (1996). "UCLA Community-Based Uveitis Study Group Causes of uveitis in the general practice of ophthalmology." *American Journal of Ophthalmology*. 121, pp. 35–46.
- [11] A. Mercanti, B. Parolini, A. Bonora, Q. Lequaglie, L. Tomazzoli. (2001). "Epidemiology of endogenous uveitis in north-eastern Italy. Analysis of 655 new cases." *Acta Ophthalmology Scand*. 79, pp. 64–68.
- [12] P. T. Merrill, J. Kim, T. A. Cox, C. C. Betor, R. M. McCallum, G. J. Jaffe. (1997). "Uveitis in the southeastern United States." *Current Eye Research*. 16, pp. 865–874.
- [13] J. Palmares, M. F. Coutinho, J. Castro-Correia. (1990) "Uveitis in northern Portugal." *Current Eye Research*. 9(Suppl), pp. 31–34.
- [14] E. S. Perkins, J. Folk. (1984). "Uveitis in London and Iowa." *Ophthalmologica*. 189, pp. 36–40. [
- [15] P. Pivetti-Pezzi, M. Accorinti, M. La Cava, R. A. Colabelli Gisoldi, M. A. Abdulaziz. (1996). "Endogenous uveitis: an analysis of 1,417 cases." *Ophthalmologica*. 210, pp. 234–238.
- [16] A. Rodriguez, M. Calonge, M. Pedroza-Seres, Y. A. Akova, E. M. Messmer, D. J. D'Amico, C. S. Foster. (1996). "Referral patterns of uveitis in a tertiary eye care center." *Arch Ophthalmology*. 114, pp. 593–599.
- [17] A. Rothova, H. J. Buitenhuis, C. Meenken, C. J. Brinkman, A. Linssen, C. Alberts, L. Luyendijk, A.

- Kijlstra. (1992). "Uveitis and systemic disease." *British Journal of Ophthalmology*. 76, pp. 137–141.
- [18] M. Santin, F. Badrinas, J. Mascaro, J. M. Nolla, O. Pujol, G. Roca, J. Valverde, J. Mana, F. Fernandez-Nogues. (1991) "Uveitis: an etiological study of 200 cases following a protocol." *Med Clin (Barc)*. 96, pp. 641–644.
- [19] R. L. Smit, G. S. Baarsma, J. de Vries. (1993). "Classification of 750 consecutive uveitis patients in the Rotterdam Eye Hospital." *Intermatopma; Ophthalmology*. 17, pp.71–76.
- [20] V. T. Tran, C. Auer, Y. Guex-Crosier, N. Pittet, C. P. Herbort. (1994). "Epidemiological characteristics of uveitis in Switzerland." *International Ophthalmology*. 18, pp. 293–298.
- [21] C. S. Foster, A. T. Vitale. *Diagnosis and Treatment of Uveitis*. Philadelphia, PA: W. B. Saunders Company, 2002.
- [22] D. A. Jabs, J. T. Rosenbaum, C. S. Foster, G. N. Holland, G. J. Jaffe, J. S. Louie, R. B. Nussenblatt, E. R. Stiehm, H. Tessler, R. N. Van Gelder, S. M. Whitcup, D. Yocum. (2000) "Guidelines for the use of immunosuppressive drugs in patients with ocular inflammatory disorders: recommendations of an expert panel." *American Journal of Ophthalmology*. 130, pp. 492–51323.
- [23] R. B. Nussenblatt, S. M. Whitcup, A. G. Palestine. *Uveitis. Fundamentals and Clinical Practice*. St. Louis, MO: Mosby, 1996.
- [24] Mark McCarty, Saleh A Alharbi. (2013). "Hypotheses." 81, pp. 773-776.
- [25] Saleh A Alharbi, Ali S Alharbi. (2015). "IgA Nephropathy improved by a new modality: MAM14 Immunotherapy: A case report in Kuwait." (2015) *ASRJETS*. Volume 14, No. 1, pp. 23-27.
- [26] T. Suzuki, Y. Kinoshita, M. Tachibana, et al. (2001). "Expression of sex steroid hormone receptors in human cornea." *Current Eye Research*. 22, pp. 28–33.
- [27] Eberhard Spoerl, Viktoria Zubaty, Frederik Raiskup-Wolf, and Lutz E. Pillunat. (November, 2007). "Oestrogen-induced changes in biomechanics in the cornea as a possible reason for keratectasia." *British Journal of Ophthalmology*. 91(11), pp. 1547–1550.
- [28] A. Boyum, J. Scand. "Isolation of mononuclear cells and granulocytes from human blood. (Paper IV)."
- [29] A. Epstein. (2000). "Keratoconus and related disorders." (PDF) *North Shore Contact Lens*. Retrieved September 8, 2007.