

Osteoradionecrosis of the Jaws after Radiotherapy Treatment in Head and Neck Area

Marcel Riznič^{a*}, Juliana Göbl^b

^{a, b} *University Hospital of Louis Pasteur, Rastislavova 43, Košice 04011, Slovakia*

^a *Email: dr.riznic@gmail.com*

^b *Email: julypetrik@gmail.com*

Abstract

Although it can be stated that the incidence of osteoradionecrosis of the jaws (ORNJ) in the last reported period decreases, the therapy of this diagnosis has a considerably more complicated continuance as with bisphosphonates osteonecrosis (BON). Oral findings are extensive, not only alveolar bones of jaws are affected by radiation, but also oral mucosa and salivary glands, resulting to a significant mucositis and xerostomia. Research in dental and oral surgery often involves materials and procedures which are capable of improving clinical outcomes in terms of percentages of success. The goal of this research was to find a treatment approach which could reduce bleeding, promote effective bone regeneration and rapid soft-tissue healing by employing resources which are easy to use at a modest cost. Patients in our study were divided into three categories: patients with newly diagnosed cancer waiting for treatment, patients after radiotherapy without signs of osteonecrosis and patients with fully developed osteoradionecrosis of jaws.

Keywords: osteoradionecrosis; radiotherapy; antibiotics; oncological disease; wound healing; oral surgery; oral medicine

1. Introduction

Osteoradionecrosis of the jaws (ORNJ) is a serious secondary injury, characterized by bone tissue necrosis and failure to heal in 3–6 months [1]. ORNJ affects the mandible more often than the upper jaw (Fig. 3). It is caused by a different blood supply. Another factor is the dosage method of radiotherapy in head and neck area. Dosage higher than 60 greys is considered dangerous in many clinical reviews.

* Corresponding author.

E-mail address: dr.riznic@gmail.com.

The largest amount of ORN is found after the radiation of tonsil carcinoma and retromolar region [2]. Curative surgery is often not possible due to the extent of tumour spread and the patient's overall condition [3]. There are three theories of ORNJ formation. The first theory was developed in 1938. The reason of the ORNJ manifestation is the penetration of the infection from the oral cavity to the changed exposed bone after radiation. This theory explains highly probable formation after the tooth extraction, however does not explain spontaneous formation after radiation [4].

The next theory recognises that it primarily does not have to be an infection, but a group of following irradiation changes of the tissue and humeral metabolism. It uses expressions such as hypoxia, hypovascularity and hypocellularity in the radiated bone [5]. The last theory dealing with ORNJ stresses the immunological processes in the bone stimulated by its local radiation, that lead to fibrotic and atrophic changes with a subsequent bone resorption [6].

The development of necrosis will show swelling, pain in the affected area, usually in occlusion, intraoral exposed bone, possibly with ulceration, oro-cutal fistula formation either incomplete or complete. One of a problematic complication is trismus, it can occur progressively after radiation therapy and is most common when the elevator muscles are in the field of radiation [7]. The development of xerostomia, dysphagia, dysgeusia, and postradiation tooth decay reduces quality of life [8]. The necrotic tissue restricts healing and provides bacteria growing and thus allows the development of the infection. The bacteria limit in time the elevated levels of pro-inflammatory mediators and cytokines and the presents of leukocytes that purifies the wound from necrotic tissue and thereby to slow down the healing [9]. The incidence and severity of mucositis will vary from patient to patient. It will also vary from treatment to treatment. It is estimated that there is 40% incidence of mucositis in patients treated with standard chemotherapy and this will not only increase with the number of treatment cycles but also with previous episodes [10].

The side effects of radiation therapy of the oral cavity tissues are divided into acute (manifestation of the healing process) and chronic which occur after the end of the treatment. Tissues with rapid proliferation of the cell population (mucosa, cutaneous or glandular epithelium) respond by acute injury. Tissues with low proliferation (ligaments, bone tissue) respond with chronic changes. In chronic wounds there is a significant lack of vitamins and trace elements because of reduced food intake, malabsorption and hypersecretion [11].

Generally patient in good overall condition, with a small number of metastases and with longer predicted survival time of a standard fractionation radiation is applied five times a week 2.0 Gy (total 6 – 40 Gy). Conversely for patients with a worse condition, with multiple metastatic cancer and lower estimated survival time, accelerated irradiation is chosen. (e.g.12x2.5 Gy, 10x3.0 Gy, 5x4.0 Gy) or only single dose (1x8.0 Gy). From the view of the expected better tolerability an accelerated mode radiation can be performed by hypofractionation (1 – 3 times per week).For tumours of the oral cavity size T1 – T3 is recommended treatment with primary brachytherapy, which should be higher than 62.5 Gy and higher than 0.5 Gy/h, respectively [12]. Brachytherapy avoids xerostomia, extensive mucositis affecting the whole oral cavity, trismus, and also permits

future radiation therapy of possible secondary tumours in the head and neck area owing to the excellent protection of surrounding healthy tissues [13].

2. Materials and methods

The methodology of the treatment was derived from the overall patient's status, extensity of the necrotized area and level of discomfort in the oral cavity and oral hygiene. Every patient was covered intravenously with antibiotics in combination of amoxiciline with clavulanic acid and metronidazole. In analgesic therapy we mostly used pyrazolone derivatives such as metamizol, opioids pentazocine, and adjuvant care secured by myorelaxans, anticonvulsants, antiemetic and local anaesthetic. In our file 63 patients had been examined in the period 2013-2015. ORNJ affected patients more frequently in the mandible than in the maxilla, in the ratio of 24:1. The reason is the difference blood supply of these anatomical regions and the dosage of radiotherapy. Dosages higher than 60 Gy were considered risky. The greatest amount of ORNJ occurred after irradiation of tonsil carcinoma and retromolar region. We consider the penetration of infection from the oral cavity into the bone after radiation as the underlying pathophysiological aspect of ORNJ. Disturbance of oral mucosa leads to irradiation changes of tissues and humoral metabolism. The immunology processes of local irritation in head and neck area led to tissue fibrosis, atrophy and subsequent resorption of alveolar bone.

2.1 Patients with newly diagnosed cancer (waiting for radiotherapy)

Patients with newly diagnosed cancer of head and neck were examined in the maxillofacial clinic before the beginning of the radiation therapy. The overall status of the oral cavity, oral hygiene standard of the patient, tooth allocation indicated for restoration with temporal fillings and teeth for extractions were evaluated. In this stage the fabrication of any prosthetic denture and dental implants were contraindicated, due to periosteal lesions and mucosal decubits that could easily occur after radiation in oral cavity. We mainly focused on the sanitation of the caries lesions, extractions, dental hygiene and detection of oral abnormalities that caused complications in the oncological therapy.

2.2 Patients after radiotherapy without signs of osteoradionecrosis development

Occasionally, pain in the jaw bone or tooth loosening may be the only symptom with no evidence of other clinical or radiological abnormalities [14]. Patients who underwent radiation of the head and neck and no ORNJ was developed were instructed of the seriousness of this diagnosis, treated only conservatively and regularly observed. It is very important to follow strict oral hygiene habits including rinses with chlorehexydine 0.12 and eliminate smoking and alcohol.

2.3 Patients with fully developed osteoradionecrosis of the jaws

Patients with fully developed ORNJ underwent procedures during the antibiotics cover, if their status allowed it. In case of smaller local oral findings, necrectomy and mucoperiosteal flap closure were performed. If local defects were wider, the surgical treatment was restricted to considerate necrectomy and sequestrectomy.

Removal of only symptomatic bony sequester with minimal disturbance of overlying soft tissue, might be appropriate [15]. In special cases (e.g. pathological fracture of mandible) the mandibulectomy was indicated. The next treatment possibility is the hyperbaric oxygen therapy (Figure 1, 2) its benefit is however denied by many authors and maybe contraindicated in tumour recurrence, poor general condition of the patient or with difficult cooperation. Previously, hyperbaric oxygen (HBO) was an important adjuvant to surgery in ORNJ. The rationale for using HBO is that the intermittent elevation of tissue oxygen tension stimulates collagen synthesis and fibroblastic proliferation, promotes the growth of new capillaries, and enhances the phagocyte ability of leukocytes [16]. On the other hand there are many other results suggesting the suitability of this treatment, in addition to surgical interventions [17]. From the prosthetic point of view the acrylic splint on alginate dental impression have been proven. The splint protected sharp bone edges from dynamic processes in the oral cavity environment. Protective stent presents an appropriate support and stability, which is necessary to generate a record of the appropriate denture base surface area, flange contour, and mucosal surface and to generate a record of the lining mucosa by making an impression [18]. Therefore, the objectives of making a complete denture impression are as follows: to generate a record of all anatomical landmarks in the oral cavity; to obtain strong adhesion or retention with the mucosal surface; and to obtain an appropriate border shape to maintain the adhesion [19]. Osteoradionecrosis of the jaws forms a difficult locality to make sufficient qualitative impressions it is sometimes difficult to generate an impression that adheres strongly to the damaged bone surface or the appropriate border shape [20]. Platelet rich plasma (PRP) therapy has been proposed as a complement to conservative surgery in order to enhance bone healing. The rationale for the employment of PRP in patients affected by ORNJ is based on the thesis that the presence of growth factors constitutes a substitute stimulation to bone healing, which is similar to physiological healing. The growth factors in PRP might accelerate epithelial wound healing, decrease tissue inflammation after surgery, improve the regeneration of bone and soft tissues, and promote tissue vascularization. The additional advantages related to the use of this product are its biocompatibility and safety, as an autologous product.

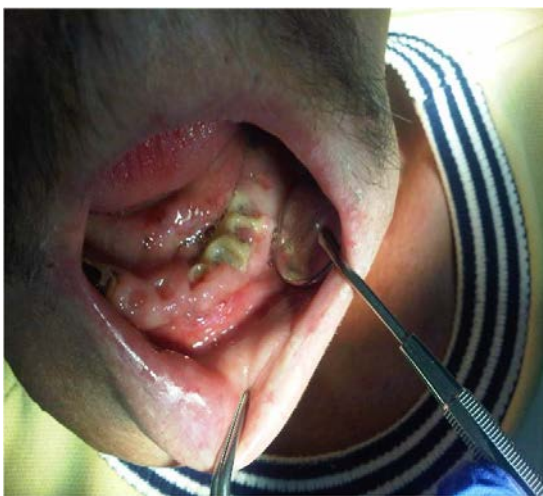

Figure 1: ORN of the mandible

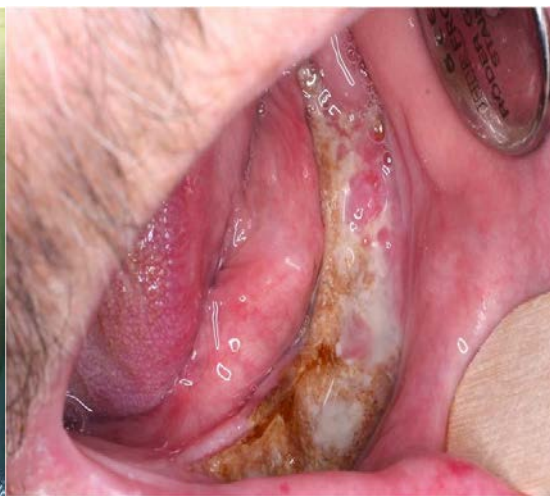

Figure 2: Result of the HBO therapy after 2 y.

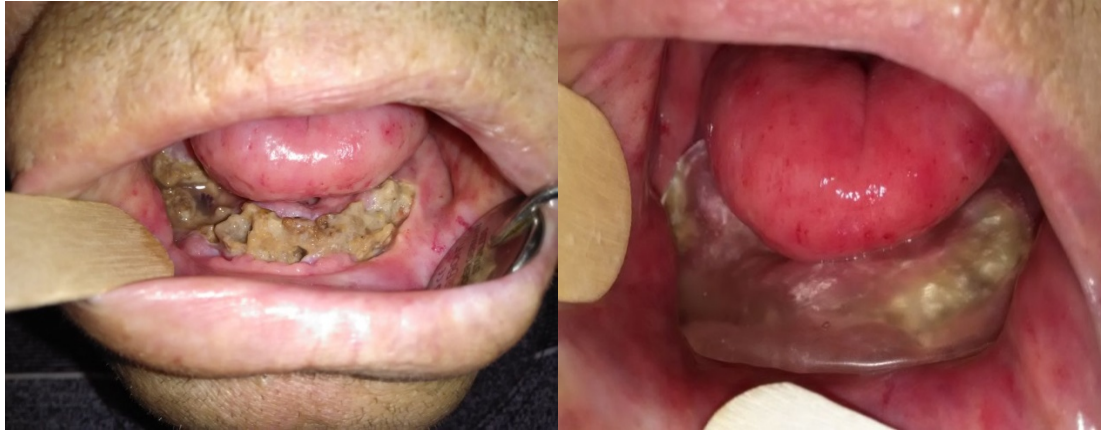

Figure 3: Extensive ORN of the mandible

Figure 4: Protective acrylic stent

3. Results

Of the group of 63 patients in the period 2013-2015 with confirmed ORNJ, 25 patients had a pathological mandible fracture. In 14 patients we managed to stabilize this complication. In 6 cases with osteosynthetic material (Figure 5, 6). In 8 cases we covered an extensive ORNJ with acrylic splint (Figure 4) since it was not possible to perform osteosynthesis due to unsatisfactory anatomical conditions. This splint not only stabilized the pathological fractures, but also protected oral mucosa against sharp bone edges of the alveolar bone. The remaining 11 patients underwent necrectomy of fractured bulges of mandible in general anaesthesia. In 18 patients we managed to stabilize the process of ORNJ by local treatment, necrectomy, egalization of sharp edges and intravenously administered antibiotics. 20 patients underwent PRP therapy with a positive outcome in follow-up period with fast mucosal healing, a reduced need for analgesics and a resolution of mouth lesions (Figure 7, 8, 9, 10, 11, 12). This improved the quality of life, food intake and speech. In this last group patients had only smaller lesions, which did not present a risk of pathological fracture and other complications. An important factor was the patient motivations to improve oral cavity hygiene and our regular recall. Patients received regular follow-ups including MRI scans, X rays and clinical exams 6–8 weeks post completion of radiotherapy, 3, 6, and 12 months thereafter. As mentioned above, the most common (36 cases) carcinoma in retro molar region and tonsils ORNJ occurred due to the relatively difficult access in relation to radiotherapy. The second most common area affected by tumour region was the base of the mouth (13 cases). Another group was patients with tongue carcinoma (10 cases). In the last group we had 4 patients with carcinoma of bucal mucosa.

4. Discussion

In terms of the oral cavity treatment it is very difficult and long lasting leaves the patient with painful exposed bone lesions in the oral cavity, which complicates his food intake and care of the oral cavity. The therapy is necessary as soon as possible and any period without therapeutical steps prolongs the treatment and worsens the overall diagnosis. Shawn and his colleagues [21] described primary prevention of ORNJ in 1999 as the most important stage in the systematic treatment of this serious and unwanted illness complication. In 2003, Sulaiman [22] published the importance of oral dental hygiene and the comprehensive dental examination prior to

initiation of radiotherapy and especially after its completion for compliance with the preventive programs and enhanced empirical experience. For these reasons there are now professional public accessible registers of osteoradionecrosis which are designed to record the newly established diagnosis and subsequent treatment. Developing ORNJ is variable and its etiopathogenesis is not until today thoroughly understood. Clinical studies aim to define the role and express the value of etiopathogenetic moments at the molecular and cellular level. Burke and his colleagues [23] recommends supporting the treatment by Pentoxifylline and vitamin E as an ideal antioxidant treatment at doses of 800mg Pentoxifylline and 1000 IU vitamin E for a minimum period of 6 month thereby supporting faster healing post radiation mucositis and soft tissue regeneration. Despite the potential risk of surgical treatment failure (immunocompromised patients, diabetes mellitus, pathological fracture etc.) the closure of sharp bone edges alveolar process appears to be the best solution.

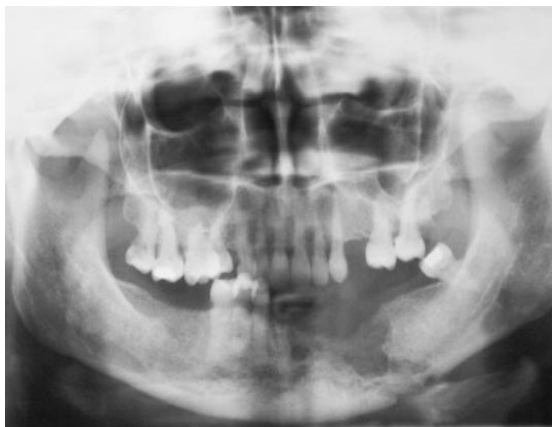

Figure 5: Pathological fracture of the mandible

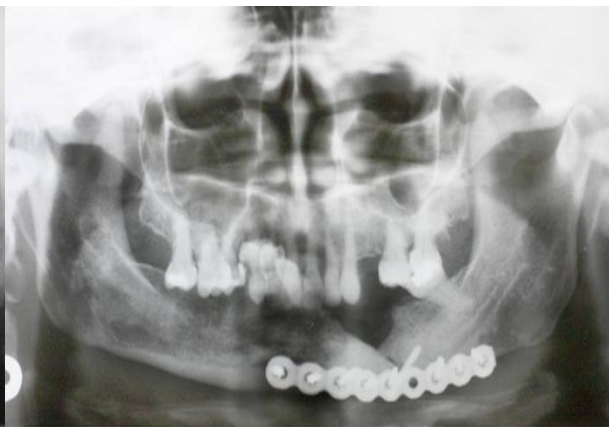

Figure 6: Osteosynthesis of the fracture

This type of treatment, however, must be preceded by strict hygiene training, patient motivation, and local debridement of necrotic bone parts. The issue of antibiotic prophylaxis is significant to help prevent infection after surgical intervention, but also the conventional extraction in the preventive face of treatment. British Association of Oral and Maxillofacial Surgeons recommend using and applying antibiotic prophylaxis in the pre surgical preparation but also in the post operative period. Despite these results, it can be stated that no global consensus on the choice, timing and length antibiotic treatment was declared [24]. ORNJ of oncological patients do not develop immediately, but after a certain time. After radiotherapy the possibility of necrosis is partly expected and the patient is informed. When recurrence of cancer after prior radiation poses a high risk to ORNJ without the possibility of surgical salvage patients face the choice between palliative chemotherapy and re-irradiation [25]. It is very encouraging that the number of ORNJ is declining due to the application of preventive measures before and during treatment with ionizing radiation [26].

5. Conclusion

The osteoradionecrosis treatment is difficult and long-lasting and leaves the patient with an exposed bone lesion which complicates food intake and oral hygiene care. Surrounding soft tissues lose their natural elasticity and are subject to post-radiation changes and tissue fibrosis. This negatively influences the treatment and aftercare of the oncological disease.

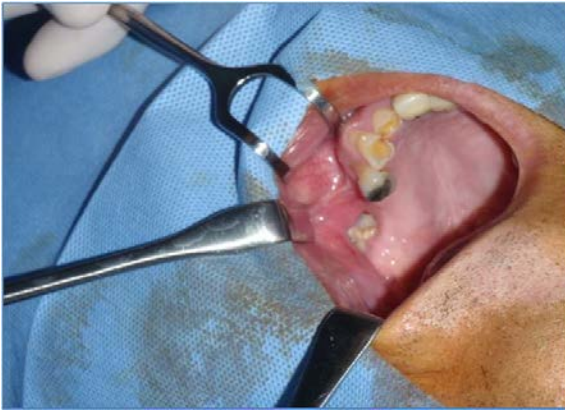

Figure 7: ORN of the upper jaw

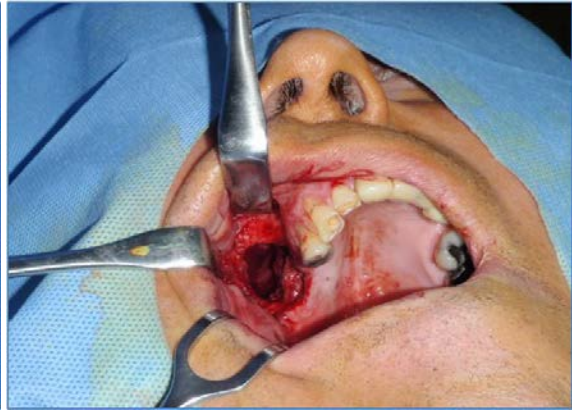

Figure 8: Extensive surgery necrectomy

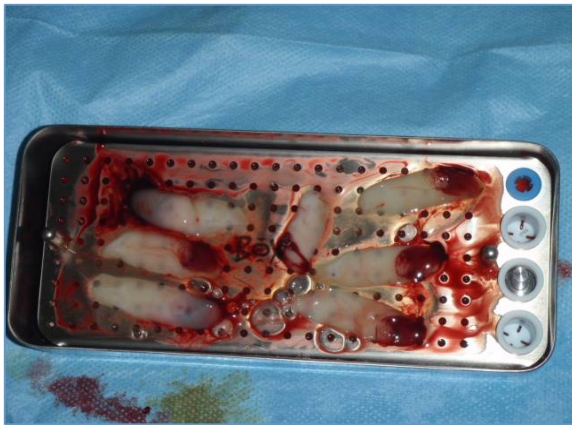


Figure 9: Platelet-Rich Plasma concentrates

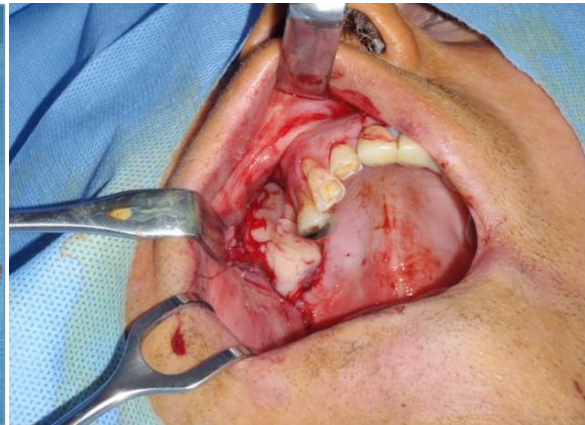

Figure 10: Application of the PRP

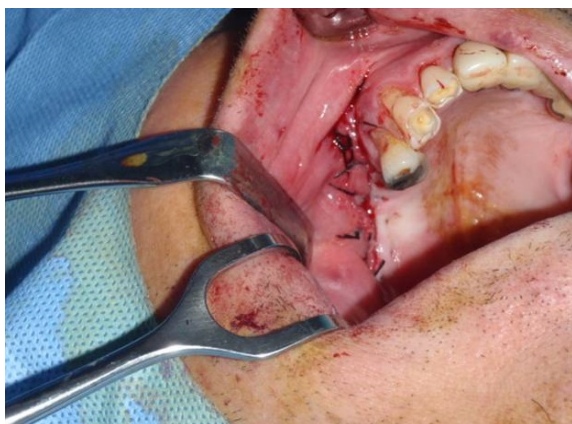

Figure 11: Closure of defect

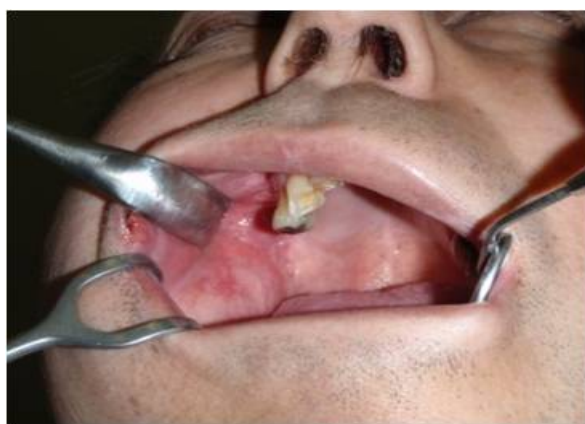

Figure 12: Status after 3 month

Extensive debridement and local flap closure seem to be unsuccessful because of hypovascularity of soft and hard tissues. In serious cases radical resection of necrotic bone and immediate free flap reconstruction is considered as the best or only solution. General health or local reasons do not always allow this type of reconstruction. Usually conservative approach with minimal surgical intervention and antibiotics cover is recommended. In spite of this, no effective therapy for osteoradionecrosis has been established, an empirical conservative therapy is recommended in the guidelines. Key to success is prevention or treatment in initial phase. It depends on cooperation between the oncologist, dentist, maxillofacial surgeon and setting a diagnosis in the shortest possible time. The combination of necrotic bone curettage and PRP application seem to be encouraging for the treatment of BRONJ, as it has demonstrated successful outcomes with minimal invasivity.

6. Recommendations

This article confirms the need to approach the patients multi - disciplinarily and very carefully with multimodal treatment including patient knowledge's about importance of the oral hygiene and also, the development of this disease process is important to establish treatment strategies that are evidenced based and associated with valid outcome data.

Acknowledgment

The incidence of complications associated with healing in terms of postoperative radiotherapy and ORNJ is relatively common and defines certain surgical methodology, which by themselves were helpful in the healing of the necrotic bone. The revelation of complications and setting a diagnosis in the shortest possible time is the most important to succeed in the therapy. PRP is an autologous preparation, utilizing the patient's own blood in a significantly small quantity. For this reason, it is safe and there have been no published references relating to the risk of infections, disease transmission (such as HIV, hepatitis, or Creutzfeldt-Jacob disease), immunogenic reactions or any other adverse effects which exist with allografts or xenografts. The osteonecrosis development is variable and its etiopathogenesis has not been clarified sufficiently. In addition, basic science research with the development of animal model system is needed to elucidate the cellular, molecular, and genetic mechanisms responsible for this process. Also, the development of this disease process is important to establish treatment strategies that are evidenced based and associated with valid outcome data.

References

- [1] DH. Brown., AW. Evans., GKB. Sandor.: "Hyperbaric oxygen therapy in the management of osteoradionecrosis of the mandible." *Adv Otorhinolaryngol* 1998., 54: p. 14 – 32.
- [2] A., Gevorgyan., K., Wong., I., Poon., N., Blanas., D.J., Enepekides., K.M., Higgins.: "Osteoradionecrosis of the mandible: a case series at a single institution." *Journal of Otolaryngology - Head & Neck Surgery* 2013, 42:46.
- [3] M. Masayuki., H. Shinya., M. Sunaho., T. Osamu., M. Keisuke., S. Toshiyuki., I. Yatsuji., H. Hiroaki.: "4 Gy single fraction palliative radiotherapy for the treatment of painful recurrent soft plate carcinoma by high-dose-rate mold brachytherapy." *Oral Oncology Extra. Volume 42, Issue 10, November 2006,*

Pages 305–307.

- [4] S. Nabil, N. Samman.: “Incidence and prevention of osteoradionecrosis after dental extraction in irradiated patients: a systematic review“. *Int J Oral Maxillofac Surg*, 40 (2011), pp. 229–243.
- [5] DK. Lam, GK. Sándor, HI. Holmes.: “A review of bisphosphonate – associated osteonecrosis of the jaws and its management.“ *J Can Dent Assoc.* 2007., 73.
- [6] WL. Watson., JE. Scarborough.: “Osteoradionecrosis in intraoral cancer. “ *Am J Roent* 1938, 40. p. 524 – 534.
- [7] Kishore, Shetty, Heber Tuf.: “Dental management of the pediatric post radiation therapy—rhabdomyosarcoma patient: Case reports and review of literature. “ *Oral Oncology Extra.* Volume 41, Issue 9, October 2005, Pages 242–248
- [8] R. De Crevoisier, J. Bourhis, C. Domenge, P. Wibault, S. Koscielny, A. Lusinchi, and his colleagues : “Full-dose reirradiation for unresectable head and neck carcinoma: experience at the Gustave-Roussy Institute in a series of 169 patients. “ *J Clin Oncol*, 16 (1998), pp. 3556–3562.
- [9] WK. Stadelmann., AG. Digenis., TR. Gordon.: “Physiology and healing Dynamics of chronic cutaneous wounds. “ *Am. J. Surg.*, y. 176, 1998., Suppl. 2A, s. 26 – 38.
- [10]UR. Maddireddy., VR. Gogula., UR. Pingali., KM. Lyyapu., S. Avula., R. Priyadarshni.: “Chemotherapy-Induced and/or Radiation Therapy-Induced Oral Mucositis-Complicating the Treatment of Cancer. “ *Neoplasia, Volume 6, Issue 5*, September–October 2004, Pages 423–431
- [11]WG. Payne, and his colleagues : “Long – term outcome study of growth factors – treated pressure ulcers. “ *Am. J. Surg.*, y. 181, 2001, no. 1, p. 81 – 88.
- [12]J.J. Mazon, J. Simon, C. Le Péchoux, and his colleagues : “Effect of dose rate on local control and complications in definitive irradiation of T1-2 squamous cell carcinoma of mobile tongue and floor of mouth with interstitial iridium 192. “ *Radiother Oncol*, 21 (1991), pp. 39–47.
- [13]S. Vratislav., L. Michael., K. Stephan., F. Rainer.: “Interstitial pulsed-dose-rate brachytherapy for head and neck cancer—Single-institution long-term results of 385 patients. “ *Brachytherapy*, Volume 12, Issue 6, November–December 2013, Pages 521–527.
- [14]M. Mehrotra, S. Ruggiero.: “Bisphosphonate complications including osteonecrosis of the jaw. “ *Hematology/The Education Program of the American Society of Hematology American Society of Hematology Education Program*, 356–60 (2006), p. 515.
- [15]S. Delenian., JL. Lefaix.: “The radiation – induced fibroatrophic process: therapeutic perspective via the antioxidant pathway. “ *Radiother Oncol* 2004, 73. p. 119 – 131.
- [16]B.R. Chrcanovic, P. Reher, A.A. Sousa, M. Harris.: “Osteoradionecrosis of the jaws—a current overview—part 2: dental management and therapeutic options for treatment. “ *Oral Maxillofac Surg*, 14 (2010), pp. 81–95.
- [17]R. Marx.: “Osteoradionecrosis: a new concept of its pathophysiology. “ *J Oral Maxillofac Surg* 1983, 41. p. 283 – 288.
- [18]A. Kitamura., Y. Kawai.: “Basic investigation of the laminated alginate impression technique: Setting time, permanent deformation, elastic deformation, consistency, and tensile bond strength tests. “ *Journal of Prosthodontic Research* Vol. 59, Issue 1, January 2015, Pages 49–54.
- [19]N. Matsumoto, F. Kawano, T. Ichikawa.: “Impression techniques of complete denture based on border

- seal." *Nippon Dental Rev*, 546 (1988), pp. 109–120.
- [20] P.C. Owen.: "Guidelines for a minimum acceptable protocol for the construction of complete dentures. " *Int J Prosthodont*, 19 (2006), pp. 467–474.
- [21] MJ. Shaw., NDK. Kumar., M. Duggal., J. Fiske., D. Lewis., T. Kinsella., T. Nisbett.: "Clinical Guidelines. The oral management of oncology patients requiring radiotherapy : chemotherapy : bone marrow transplantation. " *The Dental Faculty of the Royal College of Surgeons of England*, London 1999.
- [22] F. Sulaiman., JM. Huryn, IM. Zlotolow.: "Dental extractions in the irradiated head and neck patient: A retrospective analysis of Memorial Sloan-Kettering Cancer Centre protocols, criteria and end results. " *J Oral Maxillofac Surg* 2003; 61: 1123-1131.
- [23] M. Burke., M. Fenlon.: "Osteoradionecrosis – a review of prevention and management. " *Journal of Disability and Oral Health* (2010) 11/1 03/09
- [24] AN. Kanatas., SN. Rogers., MV. Martin.: "A survey of antibiotic prescribing by maxillofacial consultants for dental extractions following radiotherapy to the oral cavity. " *Br Dent J* 2002; 192: 157-160.
- [25] DJ. Alexandra., P. Melanie., VN. Anna., C. Naved., U. Matthias., WM. Marc., KH. Klaus., D. Jürgen.: "Re-irradiation of adenoid cystic carcinoma: Analysis and evaluation of outcome in 52 consecutive patients treated with raster-scanned carbon ion therapy. " *Radiotherapy and Oncology*. Volume 114, Issue 2, February 2015, Pages 182–188.
- [26] A. Albanese., ME. Licata., B. Polizzi., G. Campisi.: "Platelet-rich plasma (PRP) in dental and oral surgery: from the wound healing to bone regeneration. " *Immun Ageing*. 2013 Jun 13;10(1):23. doi: 10.1186/1742-4933-10-23.