

Management of Rare Case of Massive Bleeding from a Right-sided Colonic Diverticular Disease

Et-Tayab Ouazzani^{a*}, Younes Hamdouni^b, Jean-Baptiste Griot^c, Mathieu Martenot^d, Thomas Paumet^e

^{a,b}General Surgery Department , Hassan II university Hospital , Fes ,Morocco

^{a,c,d,e}Visceral Surgery Department ,Robert Boulin Hospital , Libourne , France

^aEmail: docteur.ouazzani@gmail.com

^bEmail: dryounes1983@gmail.com

^cEmail: Jean-baptiste.griot@ch-libourne.fr

^dEmail: mathieu.martenot@ch-libourne.fr

^eEmail: Thomas.paumet@ch-libourne.fr

Abstract

Bleeding related to diverticular disease occurs in 10 to 30% of patients suffering from diverticular disease. The source is more frequently in the right colon. Typically, the bleeding is massive, with 15% of the patients admitted in shock [1]. We report a case of 70 year old man presented to the emergency department with sudden rectal bleeding in need of transfusion, just after two days of non steroidal anti-inflammatory auto medication for joint pain. The patient treated with oral anticoagulation for coronary artery disease. Laboratory findings revealed very low hemoglobin of 5,1 g/dl when the patient presented at hospital. The esophagogastroduodenoscopy was normal. An abdominal computed tomography (CT) revealed contrast extravasation in the ascending colon from a solitary diverticulum .we didn't have the ability to perform an artery embolization or an endoscopic treatment especially because the patient was shocked. So the patient was operated and a right hemicolectomy was performed. After the surgery he recovered quickly and no bleeding recurred.

Keywords: Massive bleeding; diverticular disease; surgical emergency.

1. Introduction

Colonic diverticular disease is the most common cause of lower gastrointestinal bleeding .it is correlated with advanced age and comorbidities .this is why the management of this condition must proceed in a logical way to ensure the best outcome. The modality of choice to manage this emergency situation depends on the condition of the patient, the extent of ongoing hemorrhage, and local expertise.

* Corresponding author.

2. Case report

A 70 year-old man was admitted at the Emergency Department for rectal bleeding. He had a long medical history of cardiac disease and he is treated by an oral anticoagulation drug since many years. The patient has taken a non steroidal anti-inflammatory drug for a joint pain just two days before. The result of vital signs was abnormal because the deep blood loss. The physical examination showed tenderness and rebound tenderness in the right abdomen. Blood test revealed a severe anemia with 5.1g/dl of Hemoglobin. The esophagogastroduodenoscopy was normal. An abdominal computed tomography (CT) revealed contrast extravasation in the ascending colon from a solitary diverticulum. The resuscitation was began with massive transfusion protocol of a large volume of the blood product until he become stable but a few hours later, another episode of bleeding was recur. And because we didn't have the ability to perform an artery embolization or an endoscopic treatment, and the patient was shocked. We have had to perform an emergency right hemicolectomy by a laparotomy procedure (figure 1 and 2). After the surgery he recovered quickly and no bleeding recurred.

3. Discussion

Diverticular bleeding is more common when the whole colon is affected; the source is more frequently in the right colon [1]. Haemorrhage varies from occult to massive bleeding. Bleeding is related to mechanical aggression of the artery in the wall of a diverticulum[2]. It nearly always stops spontaneously, but recurrence rate is high [3]. Risk factors for diverticular bleeding include advanced age, hyperuricemia, hypertension, and steroidal or non steroidal anti-inflammatory (NSAID) drug use. In our case, we had an old patient who used a NSAID drug. In fact, the risk of diverticular bleed was increased by 15 by using the NSAID [4].The management should begun by having the medical history of the patient.the exam must include a digital rectal examination and rectosigmoidoscopy to rule out anorectal causes of bleeding.The placement a nasogastric tube or the esophagogastroduodenoscopy can help to exclude an upper gastrointestinal source of rectal bleeding. Initial tests including a complete blood count, coagulation profile, and basic metabolic panel should be obtained. In patients with diverticular bleeding, contrast-enhanced CT is mandatory before colonoscopy, because identifying the source of bleeding prior to surgery may result in a less invasive urgent colonoscopy and more effective hemostasis [4]. Diagnosis of bleeding diverticulosis has evolved during the last decade with the constant use of CT helical angiography and selective mesenteric angiography performed in those patients in whom colonoscopy is not feasible, contraindicated or incomplete. The management of bleeding colonic diverticula is very heterogeneous in the analyzed literature and it has evolved in the last 20 years with the introduction of interventional endoscopy (epinephrine injection, multipolar or heat probe coagulation, placement of endoclips and band ligation) and angiographic treatment through the use of intra-arterial infusion of vasopressin[5]. An urgent surgery is considered the treatment of choice if hemodynamic instability occurs or in case of failure of less invasive treatments such as endoscopy or angiography.In our case , we hadn't the time to send the patient in other hospital to perform an angiographic treatment. The colonic resection can be done by laparotomy or laparoscopy. The resection must be limited in case of localized colonic bleeding source .otherwise in some cases the investigation aren't able to identify exactly the source of bleeding , so the surgeon have to perform a subtotal or total colectomy. This kind of surgery is burdened with a high morbidity and mortality rate (20%) [6].this is why the management of these patients should be collegial between endoscopist, interventional

radiologist, anesthesiologist and the surgeon.

4. Conclusion

Diverticular hemorrhage is the most common etiology for lower gastrointestinal bleeding in the adult population. This disease can present the best physicians to a real challenge in the diagnosis and treatment management. Treatment protocols based on local resources and expertise should be developed to ensure the best possible outcomes for these difficult patients [6].

5. Recommendations

- The CT-scan is mandatory before colonoscopy in diverticular bleeding disease
- Colonoscopy is profitable only when bleeding stops, after a rapid clearing of the colon
- Emergency angiography detects aetiology and site of the haemorrhage in most of the patients.
- surgery must be the last resort .
- Multidisciplinary management is the key to the best outcome

References

- [1]. Gabrielli F, Chiarelli M, Guttadauro A, Poggi L, Pauna I, Lovaria A. Il sanguinamento nella malattia diverticolare del colon [Bleeding in diverticular disease of the colon]. *Ann Ital Chir.* 1998 Jul-Aug;69(4):451-7. Italian. PMID: 9835119.]
- [2]. So JB, Kok K, Ngoi SS. Right-sided colonic diverticular disease as a source of lower gastrointestinal bleeding. *Am Surg.* 1999 Apr;65(4):299-302. PMID: 10190349.]
- [3]. Keller P, Marescaux J. Hémorragie des diverticules coliques [Colonic diverticular haemorrhage]. *Rev Prat.* 1995 Apr 15;45(8):983-9. French. PMID: 7761783.
- [4]. Hayim Gilshtein, Yoram Kluger, Areen Khoury, Nidal Issa, Wisam Khoury, Massive and recurrent diverticular hemorrhage, risk factors and treatment, *International Journal of Surgery*, Volume 33, Part A, 2016, Pages 136-139, ISSN 1743-9191, <https://doi.org/10.1016/j.ijso.2016.07.076>
- [5]. Adams JB, Margolin DA. Management of diverticular hemorrhage. *Clin Colon Rectal Surg.* 2009;22(3):181-185. doi:10.1055/s-0029-1236163
- [6]. Cirocchi R, Grassi V, Cavaliere D, Renzi C, Tabola R, Poli G, Avenia S, Farinella E, Arezzo A, Vettoretto N, D'Andrea V, Binda GA, Fingerhut A. New Trends in Acute Management of Colonic Diverticular Bleeding: A Systematic Review. *Medicine (Baltimore).* 2015 Nov;94(44):e1710. doi: 10.1097/MD.0000000000001710. PMID: 26554768; PMCID: PMC4915869.

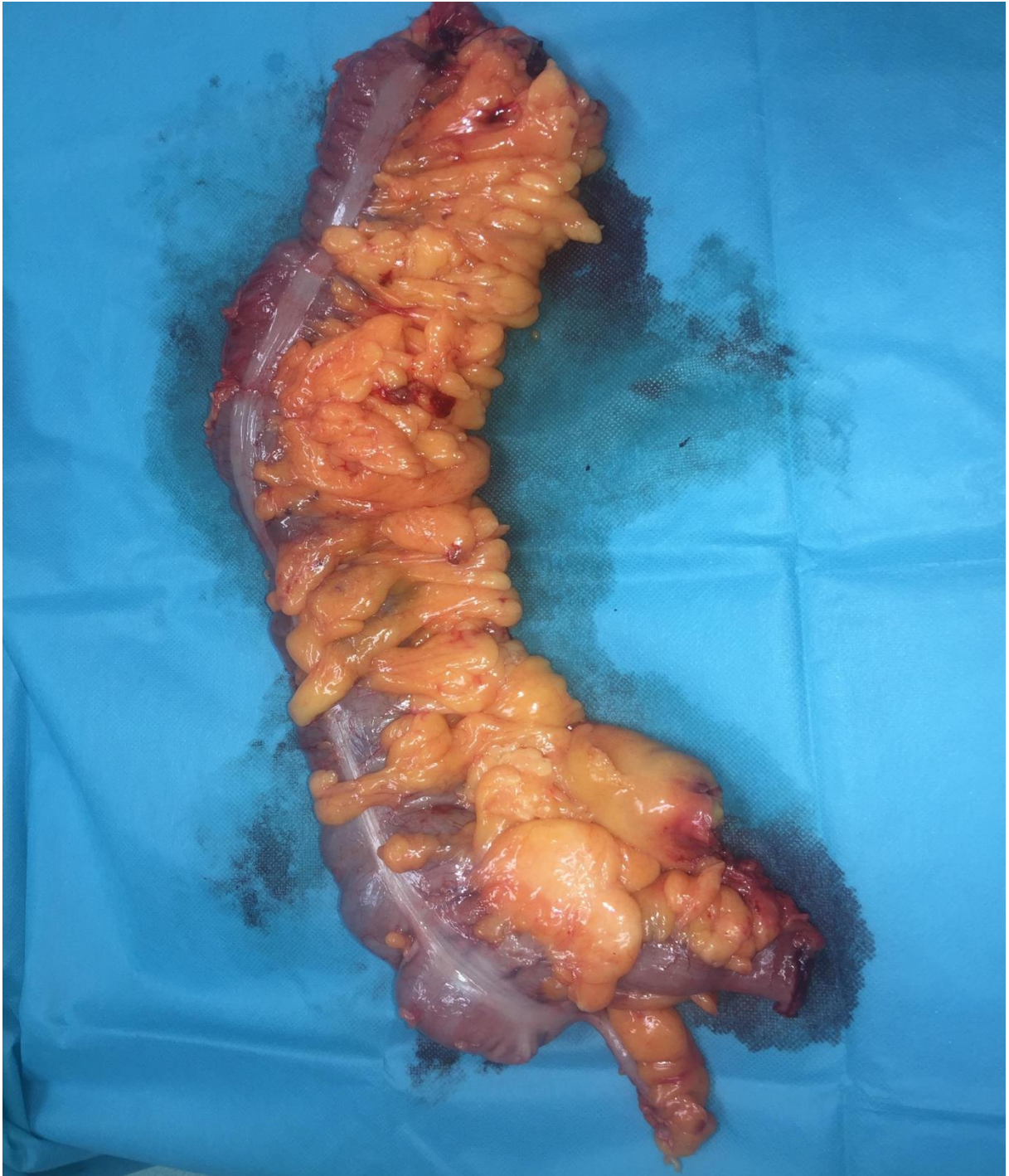

Figure 1: specimen of the hemicolectomy

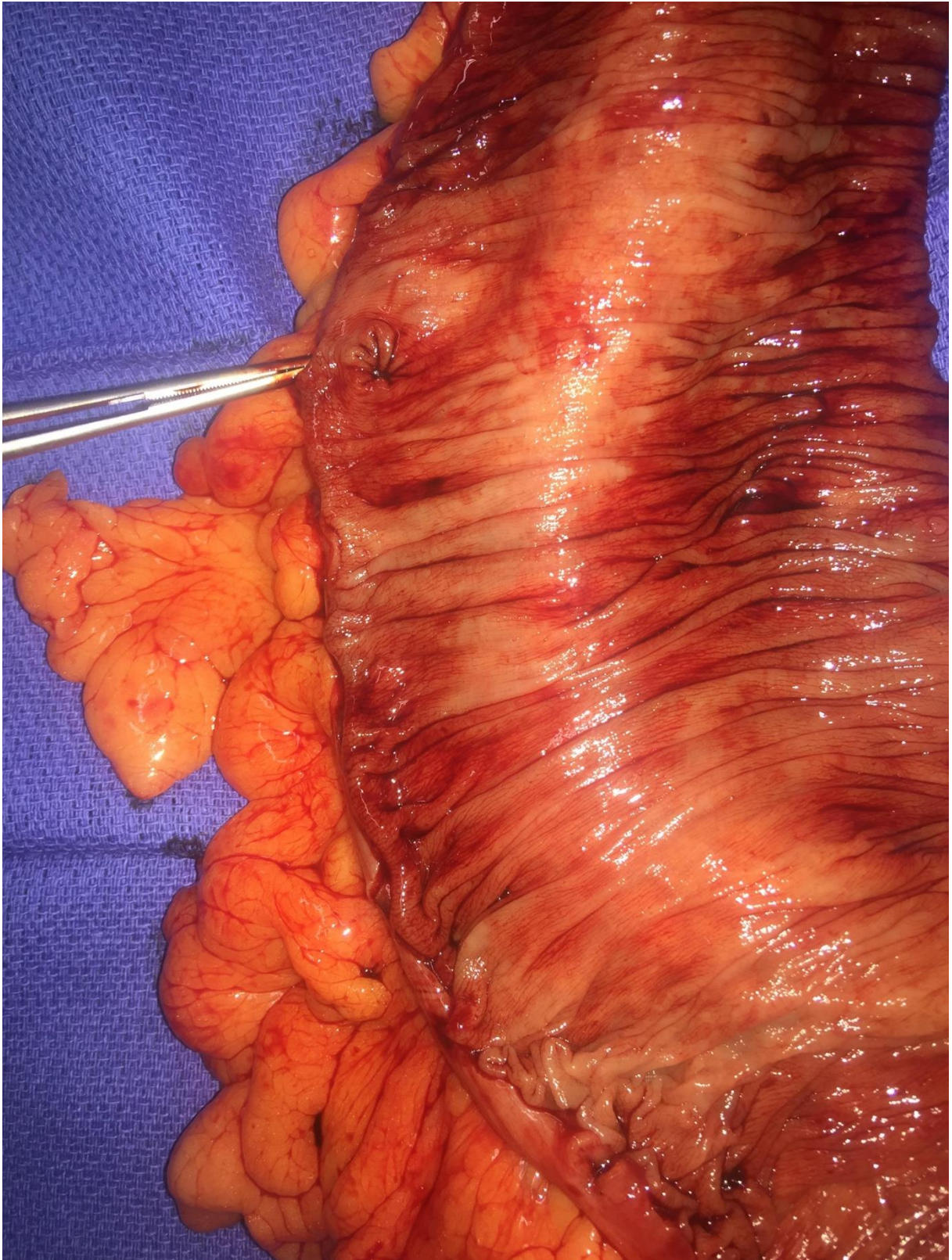


Figure 2: image of the solitary diverticulum of the right colon