

A 12-year-old Girl with a Distance Visual Acuity of 10/10 (OD) and Light Perception (OS), Found in a School for Blind People in a Town Located in Central Côte d'Ivoire: An Isolated Case?

Yves Ouattara^{a*}, Zana Diabaté^b, Liliane Ella Godé^c, Kouassi Franck Hermann Koffi^d, Raheemotu Llahi Opeyemi Babayeju^e Lekpohoro Sékongo^f

^{a,b,c,d,f,e}Ophthalmology Department. University Hospital (Training Hospital) of Bouaké, 01 BP 1174 Bouaké, Côte d'Ivoire

^aEmail: yvesouatta@yahoo.com

^bEmail: doctrzana@yahoo.fr

Abstract

Children's visual impairment is a significant barrier to their education, especially in low-income countries, due to the scarcity of specialized institutions for this purpose. We report the case of a 12-year-old girl found in a school for the blind in a town in central Côte d'Ivoire. She had stopped attending school two years earlier, due to an eye disease and was in her first year of learning braille in order to continue her education. This girl's examination showed a distance visual acuity of 10/10 in her right eye. The visual acuity in the left eye was limited to light perception. The presence of that young girl in a specialized institution for the blind education raises questions about the real motivations and eligible criteria in these institutions in socio-economic environments like ours.

Keywords: Visual Impairment; Children; Education; Côte d'Ivoire.

* Corresponding author.

1. Introduction

Basic education is a development issue for low-income countries. It must be inclusive by integrating all components of the society, with specific actions in favour of children with disabilities [1; 2]. In fact, the future socio-economic integration of a visually impaired child requires socio-educational assistance in a specialized institution with specific resources. But those resources are not always available in low-income countries [2; 3]. We report the case of a 12-year-old girl, found in a school for blind children, in a town located in central Côte d'Ivoire. That young girl had stopped attending school two years earlier, due to a vision loss in one eye, and was in her first year of learning Braille in order to continue her education. This case raises questions, on the one hand, about her parents' motivations in sending the girl in such an institution and, on the other hand, about the eligible criteria that are applied.

2. Case presentation

In May 2018, a 12-year-old girl was found in a special school for blind children during a systematic visit to identify the aetiologies of blindness, deal with curable causes and analyze the possibilities of low vision rehabilitation for those who could benefit from such assistance. This young girl had a normal schooling up to fourth grade, two years earlier. When a redness in the left eye combined with pain and decrease of her visual acuity occurred, her parents – farmers– living in rural area, provided her with a traditional cure from grounded leaves for several days without any improvements regarding the symptoms. So they took her to the nearest rural health center where an eye drops treatment, non identified, reduced the eye redness and pain with no visual recovery. A few weeks later, a whiteness appeared in her left eye. The girl's parents declared she was blind, and after a one-year school break, she was enrolled in that school for blind children where she was learning braille in order to continue her education.

The examination clearly revealed:

2.1 Right eye

Visual acuity of 10/10 for distance on the Monoyer decimal scale and P2 for near on the Parinaud scale, with slight redness of the eye, a normal anterior segment and a normal fundus.

2.2 Left eye

Visual acuity limited to four-quadrant light perception, a central corneal clouding, a total white cataract with 360° synechia. It was not possible to dilate the pupil and the fundus could not be seen, either.

We informed the school officials who were also blind people that this girl could not be classified as a blind child and she had to return to the normal system of education.

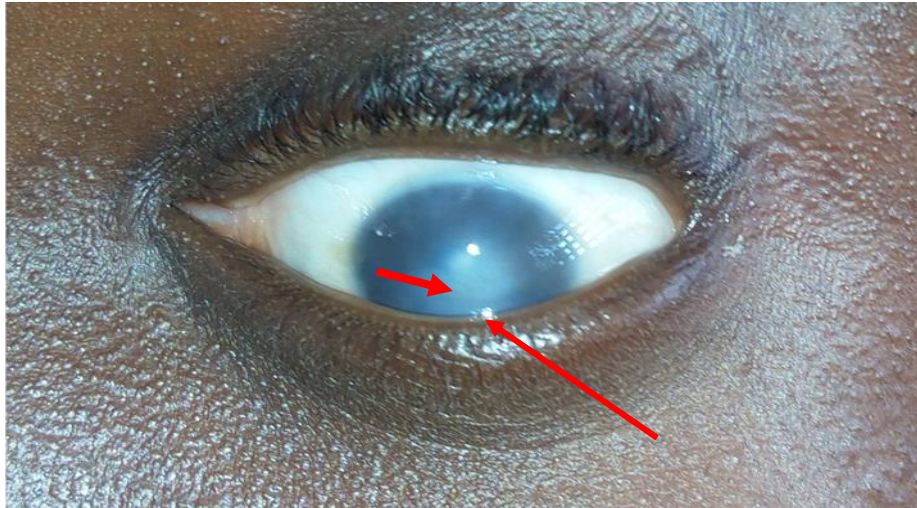


Figure 1: Leucoma (long arrow) resulting in the use of traditional eye remedy with total cataract, revealed by a leucocoria (short arrow) behind the corneal scar in the left eye of a 12-year-old school girl

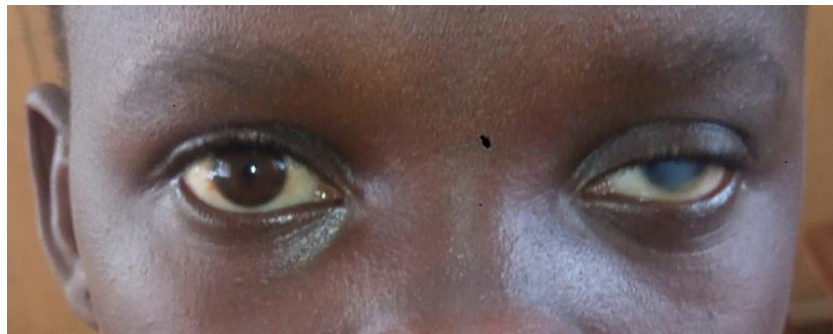

Figure 2: Twelve-year-old girl with normal right eye (VA=10/10) and corneal scar (leucoma) and total cataract in left eye (VA=light perception)

As far as the eligibility process in this school is concerned, they told us that children were admitted upon presentation of a medical certificate of blindness. A meeting with her parents was organized in order to take care of the girl on the one hand, and on the other hand to inform them that she should return to a “normal” school and leave the school for blind children. They did acknowledge that they actually wanted free education for their daughter by sending her in this school for blind children.

3. Discussion

Poverty, low level of education, and poor access to appropriate health care are the leading causes of avoidable blindness, especially in Africa [2; 4]. This is illustrated by the fact that the farming parents, locally applied a mixture of grounded plant substances on their daughter’s red and painful eye. However, the subsequent recourse to the health center, where medical treatment was able to reduce the symptomatology except for the decrease of vision, shows that there was an available resource. A good health education for the parents would have made them understood that the first step to be taken for their sick daughter, was taking her to the health center. The delay in diagnosis and treatment in a non-specialized health center probably resulted in a corneal scar and

complicated cataract. In fact, we may wonder whether this painful red eye combined with reduced visual acuity was not an anterior uveitis complicated by a cataract while the traditional substance brought about a keratitis, the healing of which resulted in a corneal opacity [5;6]. Or was it from the beginning, a keratitis aggravated by the traditional treatment, resulting in a strong inflammation of the anterior segment and a complicated cataract? Whatever may have been the mechanism, the current complications have a functional impact in this young school girl, as she can be functionally considered as a one-eye person. However, with normal visual acuity both for distance and near vision in the right eye and almost normal clinical examination, her health condition does not correspond to a state of blindness [7] requiring socio-educational assistance in a specialized institution. So, what were the reasons for her presence in a school for blind children learning braille, with the perspective of pursuing her education in braille? Certainly, the poverty of her parents could be the main motivation for enrolling their child in an institution where education is free. Still, how could they manage to do this? Probably by way of deception that consisted in providing the institution's officials (who were themselves blind) with a false medical certificate of blindness. In any case, this situation demonstrates that there was a failure in the eligibility process of residents in this school.

4. Conclusion

Poverty can motivate parents to enroll their children in specialized institutions for disabled children while they do not present any disabilities. The goal for such an approach is eventually to make these children benefit from free education due to grants. An initiative must be taken to examine institutions dedicated to children with disabilities in order to remove all cases of "disability fraud".

References

- [1]. CB Lloyd & AC Blanc. Children's schooling in sub-Saharan Africa: the role of fathers, mothers, and others. *Population development Review*, 22 (2), pp.265-98, 1996.
- [2]. WHO. Draft action plan for the prevention of avoidable blindness and visual impairment 2014-2019. *Universal eye health: a global action plan 2014-2019*. Geneva World Health Organization, 2013.
- [3]. RRA Boune, SR Flaxman, T Braithwaite, MV Cicinelli, A Das, JB Jonas, et al. Magnitude temporal trends, and projections of the global prevalence of blindness and distance and near vision impairment: a systematic review and meta-analysis. *Lancet Glob Health*, 5 (9), pp.888-97, 2017.
- [4]. A Foster, A Sommer. Childhood blindness from corneal ulceration in Africa: causes, prevention and treatment. *Bull WHO*, 64, pp.619-23, 1986.
- [5]. Y Ouattara, KV Koffi, FX Kouassi, IA Diomandé, M Soumahoro, K Safédé. Complications cornéennes des traitements des affections oculaires par les guérisseurs: à propos de 20 patients. *Rev. Col. Odonto-Stomatol. Afr. Chir Maxillo-faciale*, 15 (3), pp.50-3, 2008.
- [6]. OI Okoye, AE Aghaji, RE Umeh. Barriers to the provision of clinical low-vision services among ophthalmologists in Nigeria. *Vis Imp Res*, 9, pp.11-7, 2007.
- [7]. O Overbury, W Wittich. Barriers to low-vision rehabilitation: the Montreal barriers study. *Invest Ophthalmol Vis Sci*, 52, pp.8933-8, 2011.