

# Unusual Presentation of the Intracranial Arachnoid Cysts Posing with Treatment Dilemma: A Case Series

Abhishek Chaturbedi<sup>a\*</sup>, Jitendra Thakur<sup>b</sup>

<sup>a</sup>Associate professor and Head, Department of Neurosurgery, Manmonhan Memorial Medical College and Teaching Hospital, Swoyambhu-15, Kathmandu, Nepal

<sup>b</sup>Consultant, Department of Neurosurgery, Manmonhan Memorial Medical College and Teaching Hospital, Swoyambhu-15, Kathmandu, Nepal

<sup>a</sup>Email: [abchaturbedi@gmail.com](mailto:abchaturbedi@gmail.com)

<sup>b</sup>Email: [talk2jitu@gmail.com](mailto:talk2jitu@gmail.com)

## Abstract

A case series comprising of 3 patients with intracranial arachnoid cysts presented with atypical features raising the doubt on the symptomatic nature of the cyst. It posed dilemma on the further management of these patients. In two patients, surgical intervention to decompress the arachnoid cyst was performed which drastically improved the patient's symptoms. One patient with intracranial arachnoid cyst who has been conservatively managed persists to have symptoms.

**Keywords:** intracranial arachnoid cysts; unusual presentations; treatment dilemma.

## 1. Introduction

Arachnoid cyst of the brain is generally a benign entity without clinical significance, requiring no surgical intervention [1, 2]. The most common locations are middle cranial fossa, cerebellopontine angle, supra-sellar region and posterior fossa [3-6]. They are formed due to entrapment of cerebrospinal fluid (CSF) within two leaflets of arachnoid membrane during fetal development [7-9]. This congenital abnormality generally goes unnoticed during a person's life time except when it becomes symptomatic. When found incidentally on brain imaging, a repeat Magnetic Resonance Imaging (MRI) scan 6-8 months later shows no interval growth of the cyst and patient remains asymptomatic, the patient is discharged from neurosurgeon care considering its benign nature and non-clinical significance [5, 10].

---

\* Corresponding author.

The most common reason for the intracranial arachnoid cyst becoming symptomatic is progressive enlargement of the arachnoid cyst, hemorrhage within the arachnoid cyst or its rupture [8, 11-12]. Generally, the slow and progressive increase in size causes mass effect on the surrounding brain tissue and hence rises in intracranial pressure (ICP). Patients may present with features of raised ICP like headache, vomiting and papilledema (later optic atrophy and visual loss), another common symptom is seizure [9]. Patient may develop focal neurological deficit depending on the location of the arachnoid cyst. These are clear cut symptoms and signs suggesting symptomatic and no longer benign nature of the arachnoid cyst of the brain. Common treatment modality includes fenestration of the cyst through a burr hole, craniotomy and excision of the cyst, cysto-peritoneal shunt placement and endoscopic fenestration of the cyst into nearby cisterns [9, 13]. We present few cases with unusual presentation of the arachnoid cysts of the brain which does not fit into clear cut criteria to denote its symptomatic nature. Due to lack of definitive symptoms and signs, the neurosurgeon is faced with treatment challenges and difficult judgment calls whether or not to put these patients under the knife.

## 2. Case Reports

### 2.1. Case number 1

A 16 year's old female presented with recurrent bouts of fits of anger, mostly provoked by minor disagreement with the family members. Her abnormal behavior was not socially disruptive or danger to self or others. She had no headache, vomiting, seizures or difficulty with her vision. In nutshell, she had no localizing or lateralizing symptoms or signs. Her neurological examination including funduscopic examination of both eyes was normal. A Magnetic Resonance Imaging (MRI) of the brain with contrast with thin cuts of the temporal lobes revealed simple arachnoid cyst of the right temporal pole (**Figure 1**). It was 15 ml in volume and did not appear to compress the anterior temporal lobe harboring uncus, amygdala and hippocampal formation. There was no evidence of mesial temporal sclerosis, tumor in the right temporal lobe; atrophy, dysplastic changes or T2 signal intensity changes in the right temporal lobe. It was an unusual presentation for the arachnoid cyst and left with a judgment call on our part. Conservative management with anti-seizure medication with Levetiracetam was prescribed as temporal lobe epilepsy could not be completely ruled out. Electroencephalogram (EEG) of the brain was normal. Repeat MRI 6 months later showed persistent but static size of the cyst. Patient's anger fits were increasing in frequency but not affecting her relationship with peers except her family members were concerned deeply about her abnormal behavior. Her school performance was good and there was no anti-social behavior. The family pressed for a surgical intervention as they have previously consulted other neurosurgeons and they seemed split regarding conservative versus surgical treatment of her arachnoid cyst of the right temporal pole. We decided to intervene, and performed a cysto-peritoneal shunt using a low pressure valve system. The fluid analysis showed typical picture of normal cerebrospinal fluid (CSF) results without presence of any atypical cells or sign of infection. Repeat MRI 3 months later showed significant resolution of the arachnoid cyst (residual CSF volume 5 ml) with expansion of the anterior right temporal lobe. Volumetric analysis of the both temporal lobes was similar. Clinically, her bouts of rage had significantly reduced and family including the patient appears pleased. Patient will have regular follow-up every 6 months and if needed repeat MRI every few years.

## **2.2. Case number 2**

A 35 year's old male with recent history of frequent drop attacks presented in the outpatient department. He had no other complaints including headache, vomiting, visual disturbance, gait instability, limbs weakness, and difficulty swallowing or speech disturbance. He has no aura or prodromal features before the drop attack. He suddenly falls to the ground, sometimes hitting his head. He always has less than 1 minute of loss of consciousness, with no tonic or clonic activity of the limbs, up rolling of his eyes, bladder or bowel incontinence. After regaining consciousness, he had no confusion or headache and went about to his work like nothing happened. Patient came with MRI of the brain with contrast which showed a simple arachnoid cyst of the posterior fossa of the brain. Detailed review of the imaging with neuro-radiologist and other neurosurgeon did not suggest encysted tumor of the posterior fossa, mega cisterna magna, and epidermoid cyst or Dandy Walker malformation. The volumetric analysis from MRI was 20 ml of CSF without visible compression of posterior fossa structures like cerebellum or brain stem. Patient had contacted several neurosurgeons prior to the visit to current authors and all were of opinion that current symptom was unrelated to the pathology seen in the brain. Neurological exam was normal including funduscopic exam with ophthalmoscope of the both eyes. It is rare for posterior fossa lesion to cause seizure; still an EEG was done which was normal. It was difficult to pinpoint his distressing frequent bout of drop attacks to the posterior fossa arachnoid cyst. Patient wanted surgical intervention but we clearly stated that symptoms may not be attributed to the cyst. Performing surgery is no guarantee that he will be cured. Patient underwent cysto-peritoneal shunt placement with a low pressure valve system. CSF analysis was normal obtained during surgery. After surgery, he had no drop attacks and sigh of relief for the surgeons as the surgery did its purpose.

## **2.3. Case 3**

A 20 years old male presented to us with history of physical assault accompanied by his family members. He has been described as a gentleman with cool head except he loses his cool sometimes during verbal altercations with his friends and acquaintance. He has been involved in fight multiple times and had minor head and bodily injury in the past. He is in college and has good grades and sharp intellect as per his peers and teacher's assessment. His family is baffled why out of blue moon he develops such rage and resorts to violence which involved trivial matters?

We performed computed tomography (CT) of the head after his latest blunt head trauma and we found left frontal arachnoid cyst as proven by the follow-up MRI of the brain with contrast. The volumetric analysis put the CSF volume to 12 ml but it did not seem to have mass effect on the anterior frontal lobe. Is the arachnoid cyst an incidental finding or related to his behavioral problem? He had intact judgment, sharp intellect, good memory and stable personality. Neuro-psychiatrist evaluation and neuro-psychological testing by a psychologist did not reveal any significant abnormality. For sake of completion, EEG and funduscopic exam of both eyes were normal. After thorough consultation with peers, patients and his family members, we decided to adopt conservative management for this presumed benign entity with probably no clinical significance. He has been prescribed an atypical antipsychotic drug by the psychiatrist. He had monthly visit to the outpatient department and during 3 months of follow up, he had two incidents of physical assault. It was initiated by him for minimal

verbal altercation and luckily there was no hit to the head. A repeat MRI during his last follow-up visit 6 months after his initial visit showed no interval change in the left frontal arachnoid cyst. At this point, we have no reason to believe his current behavioral anomaly is related to the cyst, neither can we rule out completely that his symptomatology is not due to the brain lesion.

### **3. Discussion**

Arachnoid cysts of the brain are classically benign congenital entities with no clinical significance [1, 2]. However, sometimes due to slow and progressive enlargement of the cyst with accompanying pressure effect, patients will have symptoms [8, 12]. There are generally features of raised ICP, seizure and focal neurological deficit depending on the location of the cysts [7, 9]. Our case series basically raises certain atypical presentations which the authors attribute secondary to the arachnoid cysts. All the patients in our series had stable size of the arachnoid cyst over time with clear imaging evidence of lack of mass effect on surrounding brain tissue. No patient had features of raised ICP which includes headache, vomiting and papilledema which can progress to optic nerve atrophy and visual loss. No evidence of focal seizures on EEG, neither localizing nor lateralizing signs strongly suggestive of focal neurological deficit secondary to compression from the arachnoid cysts. In none of the patients, Two patients with arachnoid cysts who were treated surgically had significant improvement in their symptoms suggesting it was related to the brain lesion. One patient who was not operated still has persisting symptoms and we wonder if the patient will improve if we decompress or remove the cyst. Our case series highlights the absence of typical symptoms and signs of symptomatic arachnoid cysts of the brain. This creates a treatment dilemma in the mind of treating neurosurgeons. One has to take a judgment call and bear the pain of unnecessarily putting the patient through knife if the symptom does not resolve post-operatively. Not to mention the disappointment in the face of the patient and his/her family members. The limitation of this study is one of the patient with intracranial cyst which has not been operated, his symptoms can't be ascribed with confidence to the intracranial arachnoid cyst. If his cyst was excised or decompressed and symptoms resolved, we will be more vocal in attributing his symptoms to the cyst. This case series has small sample size. A large case series with over dozen patients who became asymptomatic after cyst operation may have given us great confidence to proclaim that the not so definitive symptoms in a patient with intracranial arachnoid cyst may be part of its symptomatic nature.

### **4. Conclusion**

After exploring the current case series, we are of the opinion that some symptomatic arachnoid cysts of the brain lack typical features of mass effect. This carries a treatment dilemma and the chance of unnecessarily putting the patient through surgery if they do not improve post-operatively. Conversely, not operating on them may deprive the patient of being better if the decompression of the cyst drastically improves their symptoms.

### **5. Recommendations**

The authors recommend to entertain the atypical symptoms in a patient with intracranial arachnoid cyst may be attributable to the pathology. If the patient's symptoms persists despite stable size of the arachnoid cyst over

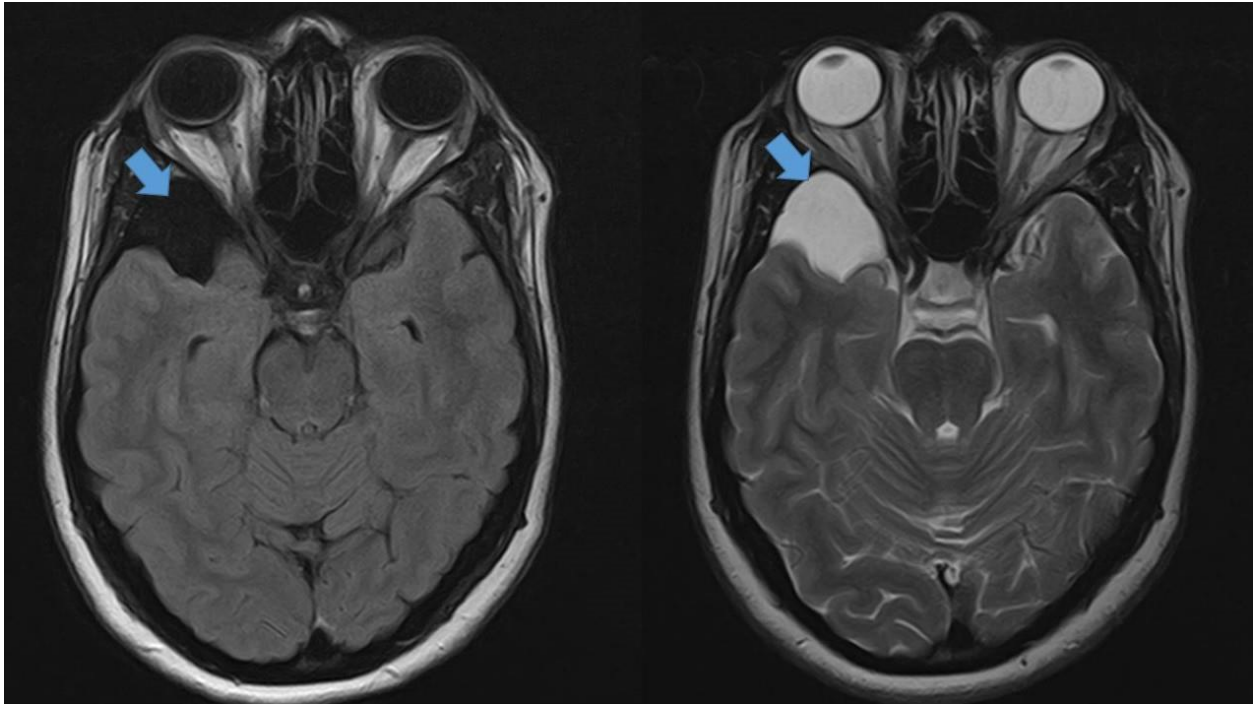
time, the cyst should be considered symptomatic. A surgical intervention to decompress or excise the cyst should be strongly considered. This may relieve the symptoms (as current case series), suggesting the not so definite symptoms was probably features of symptomatic the arachnoid cyst.

### Acknowledgement

We thank Dr. Roshan Piya, a neuro-radiologist who helped in providing valuable information and opinion regarding patient's MRI involved in this series.

### References

- [1]. WN Al-Holou, S Terman, C. Kilburg et al. "Prevalence and natural history of arachnoid cysts in adults". *J Neurosurg*, 118:222–231, 2013.
- [2]. WN Al-Holou, A Yew, Z Boomsaad, et al. "Prevalence and natural history of arachnoid cysts in children". *J Neurosurg*, 5:578–585, 2010.
- [3]. KG Go, H-J Houthoff, EH Blaauw et al. "Arachnoid cysts of the Sylvian fissure". *J Neurosurg*, 60:803–813, 1984.
- [4]. E Galassi, F Tognetti, G Gaist et al. "CT scan and metrizamide CT cisternography in arachnoid cysts of the middle cranial fossa: Classification and pathophysiological aspects". *Surg Neurol*, 17:363–369, 1982.
- [5]. M Kumagai, N Sakai, H Yamada et al. "Postnatal development and enlargement of primary middle cranial fossa arachnoid cyst recognized on repeat CT scans". *Childs Nerv Syst*, 2:211–215, 1986.
- [6]. JR Little, MR Gomez, CS MacCarty. "Infratentorial arachnoid cysts". *J Neurosurg*, 39:380–386, 1973.
- [7]. SS Rengachary, I Watanabe, CE Brackett. "Pathogenesis of intracranial arachnoid cysts". *Surg Neurol*, 9:139–44, 1978.
- [8]. L Basaldella, E Orvieto, AP Dei Tos et al. "Causes of arachnoid cyst development and expansion". *Neurosurg Focus*, 22:E4, 2007.
- [9]. JA Gosalakkal. "Intracranial arachnoid cysts in children: A review of pathogenesis, clinical features, and management". *Pediatr Neurol*, 26:93–98, 2002.
- [10]. A Barkovich. "Diagnostic Imaging: Pediatric Neuroradiology". Thieme, New York: 2014
- [11]. M Cress, JRW Kestle, R Holubkov et al. "Risk factors for pediatric arachnoid cyst rupture/hemorrhage". *Neurosurgery*, 72:716–722, 2013.
- [12]. SH Halani, MG Safain, CB Heilman. "Arachnoid cyst slit valves: The mechanism for arachnoid cyst enlargement". *J Neurosurg Pediatr*, 12:62–66, 2013.
- [13]. ME Fewel, ML Levy, G McComb. "Surgical treatment of 95 children with 102 intracranial arachnoid cysts". *Pediatr Neurosurg*, 25:165–173, 1996.



**Figure 1:** MRI of the brain FLAIR sequence (left image) and T2 weighted sequence (right image) shows attenuation of CSF signal and hyper intensity in the right temporal pole (large blue arrows) respectively. This suggest an intracranial arachnoid cyst. Diffusion weighted images (not shown) did not show restricted diffusion in the region of the cyst.